



Acute Hydronephrosis owing to A Giant Fecaloma in an Older Patient

Narae Joo¹, Hyung Seok Lee²

¹Department of Nephrology, Hanmaeum General Hospital, Jeju, Korea

²Division of Nephrology, Department of Internal Medicine, Hallym University Sacred Heart Hospital, Anyang, Korea

Corresponding Author:

Hyung Seok Lee, MD

Division of Nephrology, Department of Internal Medicine, Hallym University Sacred Heart Hospital, 22

Gwanpyeong-ro 170beon-gil, Dongang-gu, Anyang 14068, Korea

E-mail: pcsacred@gmail.com

ORCID:

<https://orcid.org/0000-0001-6380-9243>

Received: August 8, 2020

Revised: September 4, 2020

Accepted: September 5, 2020

Hydronephrosis with acute urinary tract obstruction can lead to serious complications such as obstructive nephropathy or pyelonephritis. We report the first case of hydronephrosis caused by a giant fecaloma in an 83-year-old woman accompanied with chronic constipation in Korea. The patient with a fever presented to the emergency room and was diagnosed with right hydronephrosis. Computed tomography revealed a markedly dilated rectum with a giant fecaloma compressing the right vesicoureteric junction. Hydronephrosis was resolved through manual disimpaction of the fecaloma and simultaneous lavage with rectal tubes, which improved the acute pyelonephritis and renal function. Chronic constipation can lead to giant fecaloma threatening urinary tract patency, especially in older patients with immobility or dehydration. Therefore, clinicians should consider this condition as a rare but possible cause of hydronephrosis in older patients with chronic constipation.

Key Words: Hydronephrosis, Fecal impaction, Elderly

INTRODUCTION

Acute urinary tract obstruction can cause acute kidney damage and urinary tract infections, which can lead to potentially fatal complications. Although rare, acute urinary tract obstruction can be caused by compression of the gastrointestinal (GI) tract. Some cases of acute urinary tract obstruction by giant fecalomas caused by chronic constipation have been reported in patients with immobility and dehydration.¹⁾ In addition, constipation and fecal impaction are common clinical problems in older adults.²⁾

Even with its clinical relevance, chronic constipation is rarely suspected as a predisposing cause of urinary tract obstruction. To date, there have been no reports of fecaloma-related acute hydronephrosis owing to chronic constipation in Korea. Here, we report a case of acute hydronephrosis owing to a giant fecaloma in an older patient.

CASE REPORT

An 83-year-old woman with a fever presented to the emergency room. She had a 10-year history of chronic constipation and was in a

long-term bedridden state owing to a previous history of right femur fracture, cerebral infarction, and dementia. She had no history of abdominal surgery, inflammatory bowel disease, or anatomical abnormalities of the GI tract. Her blood pressure was 130/70 mmHg; heart rate, 81/min; respiratory rate, 22/min; and body temperature, 37.8°C. The patient was mentally alert but was not able to follow instructions owing to severe dementia. She had a history of cerebral infarction with neurologic sequelae of left hemiplegia and was in a bedridden state owing to a right femur fracture following a fall that occurred 1 month earlier.

Physical examination of the patient revealed diffuse abdominal tenderness, and a firm and huge mass was palpable between her pubic bone and umbilicus. She had no rebound tenderness. Bowel sounds were hypoactive. Blood test results were as follows: white blood count, 8,700/ μ L with neutrophilia (83.4% white blood cells [WBCs]); hemoglobin, 11.7 g/dL; and C-reactive protein, 65.3 mg/L (markedly increased). Electrolytes and thyroid function test results were normal. Proteinuria 2+, hematuria 3+ (red blood cell > 100 in microscopic examination), and pyuria (WBC count 50–99/ μ L in microscopic examination) were detected following the

urine analysis.

Serum blood urea nitrogen (BUN) and creatinine concentrations were mildly increased to 43.0 mg/dL and 0.93 mg/dL, respectively. Blood and urine microbiological cultures grew *Escherichia coli* sensitive to all tested antibiotic agents. A Foley catheter was introduced into the urinary bladder, and the remaining urine volume was 50 mL. Computed tomography revealed a markedly dilated rectum with a giant fecaloma compressing the right lower ureter and vesicoureteric junction, resulting in right hydronephrosis (Fig. 1). Through the manual release of the fecaloma and simultaneous enema with rectal tubes, fecal impaction and rectal dilatation were resolved. Subsequently, hydroureteronephrosis was resolved, which was confirmed by ultrasonography (Fig. 2). Acute pyelonephritis and renal function improved and the patient's BUN and serum creatinine concentrations decreased to 19.6 mg/dL and 0.69 mg/dL, respectively. In addition, the serum C-reactive protein concentration decreased to 7.77 mg/L. The patient was discharged in good medical condition with normal renal and bowel functions.

The present case report was reviewed by the Institutional Review Board of Hallym University Sacred Heart Hospital (No. HALLYM 2020-05-011), and informed consent was obtained from the patient for publication.

DISCUSSION

Fecal impaction can be caused by GI tract damage owing to Hirschsprung disease, prior intestinal surgeries, and anorectal malformations.³⁻⁵⁾ However, chronic constipation is also a common cause of fecal impaction, especially in older adults.⁶⁾ A fecaloma is a mass of inspissated

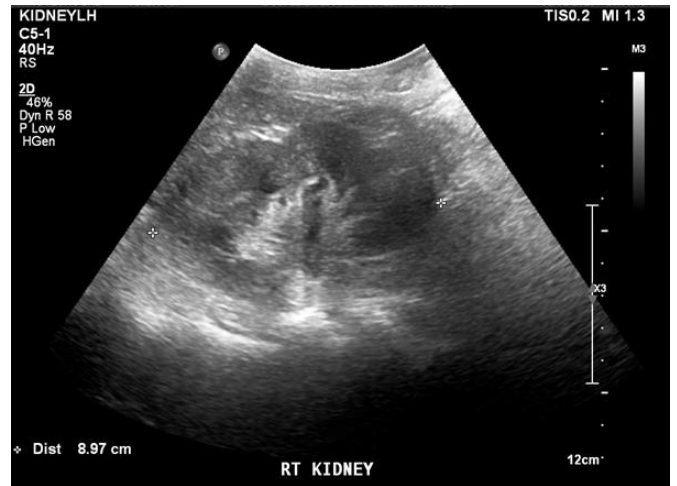

Fig. 2. Kidney ultrasound demonstrating a longitudinal view of normal-sized kidneys and a shape with the resolution of hydronephrosis in the right kidney.

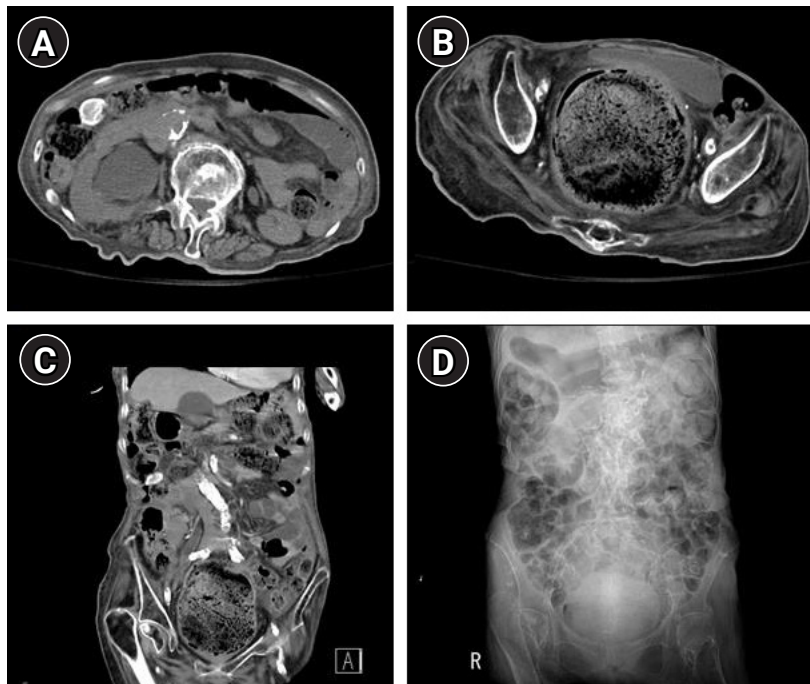


Fig. 1. Hydroureteronephrosis caused by a giant fecaloma in the rectum. (A) Computed tomography (CT) of the abdomen-pelvis showing hydronephrosis in the right kidney. (B) CT of the abdomen-pelvis showing a huge distended rectum containing a giant fecaloma pushing the urinary bladder anteriorly and compressing the vesicoureteric junction. (C) CT of the abdomen-pelvis showing right hydronephrosis owing to a markedly dilated rectum caused by the huge fecaloma. (D) Giant fecaloma is visible in the kidney-ureter-bladder image.

sated stool that results from the accumulation of feces in the rectum or rectosigmoid colon. Fecalomas are much harder in consistency than a fecal impaction and can cause a mass effect that compresses adjacent anatomical structures, leading to potentially fatal complications unless appropriately treated.^{1,7)} In the literature, fecalomas can reportedly lead to bowel ischemia, bowel perforation, and peritonitis.^{7,8)} However, obstructive nephropathy with compression by fecalomas owing to chronic constipation is rarely reported.^{9,10)} Fecaloma can result in a marked dilatation of the rectosigmoid colon, subsequently leading to extrinsic ureteral compression and acute urinary tract obstruction owing to anterior displacement of the bladder base.¹¹⁾ Bedridden patients with immobility owing to neurological or traumatic sequelae are at a higher risk of developing urinary tract obstruction caused by chronic constipation-induced fecalomas, especially if they are superimposed by insufficient fluid intake, dehydration, or administration of drugs that decrease GI tract motility.¹²⁻¹⁴⁾ Moreover, patients with schizoaffective disorders who are receiving antipsychotic, anticholinergic, tricyclic antidepressant, and antiserotonergic medication are also at a higher risk.¹²⁻¹⁵⁾ Consistent with these reports, our patient was also bedridden owing to a previous cerebral infarction and femur fracture; she also had a history of chronic constipation. Moreover, her medical records confirmed that the patient had been taking analgesics for the femur fracture. Because it was difficult to communicate with the patient owing to advanced dementia, we assumed that she could not complain about her symptoms until hydronephrosis resulting from the giant fecaloma occurred.

Besides unilateral or bilateral acute kidney injury, urinary tract obstruction caused by giant fecalomas can lead to acute pyelonephritis or emphysematous pyelonephritis; therefore, urgent treatment, including the removal of the cause, is necessary.¹⁶⁾ Most fecal impactions are successfully treated by conservative methods such as laxatives, manual disimpaction, including digital evacuation, or transrectal enemas.^{17,18)} In cases refractory to conservative methods, an endoscopic approach for removing fecalomas has also been described.^{19,20)} Surgery is required only in severe cases.¹⁵⁾ Fortunately, conservative treatment with rectal enema and digital evacuation was successful in our patient.

Although extremely rare, fecal impaction should be considered in the differential diagnosis of acute obstructive nephropathy, especially in older patients with limited mobility, history of cerebrovascular accidents, and intake of agents that decrease bowel movements. Chronic constipation can lead to giant fecaloma threatening urinary tract patency, especially in older people with immobility and dehydration or those who are taking analgesics that decrease GI motility. Although giant fecalomas are rare causes of acute obstructive nephropathy or pyelonephritis, physicians should consid-

er them as possible causes of hydronephrosis in older patients with chronic constipation.

ACKNOWLEDGMENTS

CONFLICT OF INTEREST

The researchers claim no conflicts of interest.

AUTHOR CONTRIBUTIONS

Conceptualization, HSL; Data curation, NJ, HSL; Investigation, NJ, HSL; Methodology, NJ, HSL; Project administration, HSL; Supervision, HSL; Writing-original draft, NJ, HSL; Writing-review & editing, NJ, HSL.

REFERENCES

1. Caiazzo P, De Martino C, Del Vecchio G, Di Lascio P, Marasco M, Laviani F, et al. Megacolon for a giant faecaloma with unlucky outcome: case report and review of the literature. *Ann Ital Chir* 2013;84:319-22.
2. Oh SH. Constipation in the elderly. *J Korean Geriatr Soc* 2001; 5:209-17.
3. Altomare DF, Rinaldi M, Sallustio PL, Armenise N. Giant fecaloma in an adult with severe anal stricture caused by anal imperforation treated by proctocolectomy and ileostomy: report of a case. *Dis Colon Rectum* 2009;52:534-7.
4. Cheng M, Ghahremani S, Roth A, Chawla SC. Chronic constipation and its complications: an interesting finding to an otherwise commonplace problem. *Glob Pediatr Health* 2016;3: 2333794.X16648843.
5. Park JS, Park TJ, Hwa JS, Seo JH, Park CH, Youn HS. Acute urinary retention in a 47-month-old girl caused by the giant fecaloma. *Pediatr Gastroenterol Hepatol Nutr* 2013;16:200-5.
6. Serrano Falcon B, Barcelo Lopez M, Mateos Munoz B, Alvarez Sanchez A, Rey E. Fecal impaction: a systematic review of its medical complications. *BMC Geriatr* 2016;16:4.
7. Celayir MF, Koksall HM, Uludag M. Stercoral perforation of the rectosigmoid colon due to chronic constipation: a case report. *Int J Surg Case Rep* 2017;40:39-42.
8. Ouaisi M, Sielezneff I, Benoist S, Pirro N, Cretel E, Chaix JB, et al. Lethal fecaloma. *J Am Geriatr Soc* 2007;55:965-7.
9. Perfecto Valero A, Serrano Hermosilla C, Aranda Escano E, Tellaeché de la Iglesia M. Right hydronephrosis secondary to fecal impaction. *Cir Esp* 2019;97:407.
10. Hernandez Garcia E, Torres Sanchez MJ, Gomez Sanchez J. Fecaloma as a cause of acute renal failure. *Rev Clin Esp* 2019;219: 462-3.

11. Kerrigan DD, Lucas MG, Sun WM, Donnelly TC, Read NW. Idiopathic constipation associated with impaired urethrovesical and sacral reflex function. *Br J Surg* 1989;76:748-51.
12. Knobel B, Rosman P, Gewurtz G. Bilateral hydronephrosis due to fecaloma in an elderly woman. *J Clin Gastroenterol* 2000;30:311-3.
13. Tu KC, Kuo JR. Fecaloma causing megacolon and bilateral hydronephrosis. *Formos J Surg* 2020;53:70-3.
14. Kim MY, Etherton-Ber C, Kim CB, Yoon JL, Ga H, Kim HC, et al. Development of a Consensus List of Potentially Inappropriate Medications for Korean Older Adults. *Ann Geriatr Med Res* 2018;22:121–129.
15. Khan MA, Dar HA, Shah AH, Javid G, Singh B, Sheikh NA, et al. Fecaloma presenting as huge abdominal mass. *JGH Open* 2019;4:294-5.
16. Abi Abdallah M, Raad N, Yarak N, Noujeim JP, Noujeim A. Emphysematous pyelonephritis caused by a giant fecaloma. *Case Rep Urol* 2019;2019:8743525.
17. Curro G, Lazzara C, Latteri S, Bartolotta M, Navarra G. Supergiant fecaloma as manifestation of chronic constipation. *G Chir* 2017;38:53-4.
18. Yamasaki M, Funaishi K, Hattori N. Giant fecaloma causing anorexia and dysuria. *Clin Gastroenterol Hepatol* 2020;18:A30.
19. Ghosh G, Shah S, Maltz C. A case of a giant fecaloma. *Clin Gastroenterol Hepatol* 2018;16:e48.
20. Sakai E, Inokuchi Y, Inamori M, Uchiyama T, Iida H, Takahashi H, et al. Rectal fecaloma: successful treatment using endoscopic removal. *Digestion* 2007;75:198.