

Vivid Dreaming after Acetyl-L-Carnitine Administration: A Report of Two Cases

Hyeyun Kim, MD¹, Do Young Yoon, MD², Doo Yong Park, MD², Hyun Jeong Han, MD²

¹Department of Neurology, Catholic Kwandong University College of Medicine, Gangneung,

²Department of Neurology, Myongji Hospital, Goyang, Korea

Acetyl-L-carnitine (ALC), an acetylated form of L-carnitine, is able to influence the activity of cholinergic neurons, cell membrane stabilization and enhancing mitochondrial function. A 52-year-old woman was referred to neurology clinic for memory impairment within 1 year. She was administered ALC as dose of 1,500 mg per day for improving memory decline. After 14 days from administrating ALC, she complained vivid dreams at every night. Vivid dream was disappeared after ceasing ALC. Another patient, a 72-year-old man, visited neurology clinic for cognitive decline for 2 years. After 20 days from administering ALC with dose of 1,500 mg per day, he also suffered from vivid dreams at every night. His previous stable sleep was also restored after ceasing ALC. ALC supplementation may present vivid dreams as a side effect. Possibility of vivid dream as a side effect should be considered during the management with oral ALC.

Key Words: Carnitine, Dreams

INTRODUCTION

Acetyl-L-carnitine (ALC) is an acetylated form of L-carnitine. ALC is able to influence the activity of cholinergic neurons, cell membrane stabilization and enhancing mitochondrial function¹⁾. Previous studies have been showed beneficial outcomes of oral ALC supplementation in patients with cognitive decline in patients with dementia, such as Alzheimer disease and elderly patients with fatigue²⁻⁴⁾. However, there have been a little cautious observation for drug side effects, as compared with widely used drugs for patients with behavioral and cognitive deficits. Here, we report two patients who developed vivid dreaming after oral intake of ALC to improve cognitive function.

CASE REPORTS

CASE 1

A 52-year-old woman was referred to neurology outpatient clinic for memory impairment, developed within 1 year. She had no pertinent medical history including hypertension and diabetes. She had no drug history as well as nutritional supplement. She denied family history of dementia and neurodegenerative disease. Her Mini-mental Status Examination (MMSE) score was 27 out of a possible 30 points; she lost two points on the serial sevens from 100 and one point on the 3-stage command. Assessment of her activity of daily living (ADL) was normal. Brain magnetic resonance images (MRI) showed no significant findings, such as mild cerebral atrophic changes explainable to memory impairment (Fig. 1A). She was administered with ALC, dose of 1,500 mg per day, for improving memory decline. After 14 days from administrating ALC, she complained of vivid dreams at every night. She described that her dreams were too vivid and bothersome at night. The

▶ Received: May 2, 2013 ▶ Revised: June 24, 2014

▶ Accepted: July 18, 2014

Address for correspondence: Hyun Jeong Han, MD, PhD
Department of Neurology, Myongji Hospital, 55 Hwasu-ro
14beon-gil, Deokyang-gu, Goyang 412-826, Korea
Tel: +82-31-810-5403, Fax: +82-31-969-0500
E-mail: neurohan5403@gmail.com

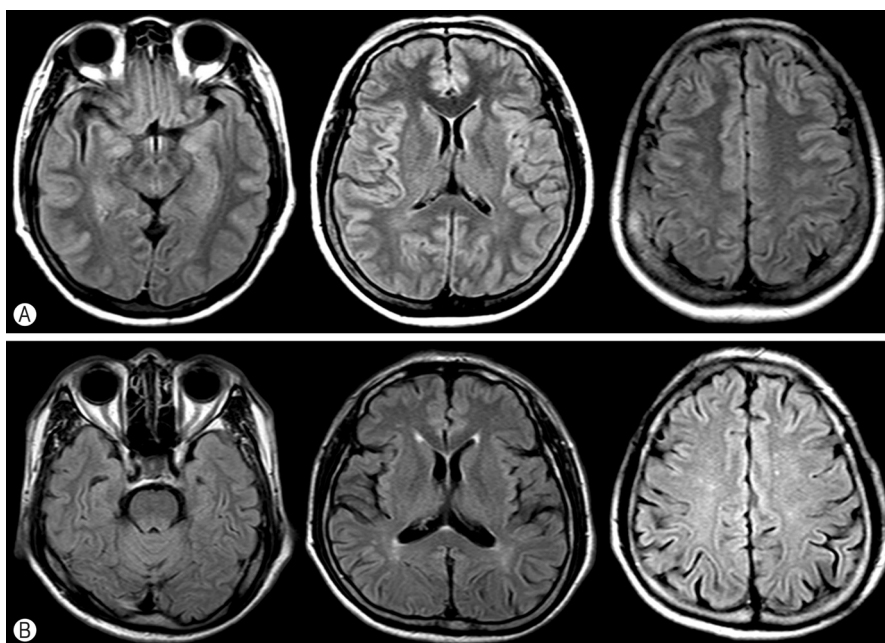


Fig. 1. Brain magnetic resonance images. (A) Fluid-attenuated inversion recovery (FLAIR) axial images from case 1 were no significant brain atrophic change. (B) FLAIR axial images from case 2 showed mild ischemic lesions in periventricular white matter and mild atrophic change.

contents of her dream included several familial or unfamiliar people wearing vivid color clothes. Her vivid dreams had disappeared after ceasing the ALC medication.

CASE 2

A 72-year-old man visited a neurology clinic due to cognitive decline for 2 years. He had no pertinent medical history, such as hypertension or diabetes mellitus. He denied any drug history as well as nutritional supplement. He also denied family history of dementia and neurodegenerative disease. His brain MRI showed mild ischemic changes in periventricular area and subcortical white matters and mild global atrophy (Fig. 1B). He performed neuropsychiatric function test. His MMSE was 25 points. He lost 2 points on memory recall and 2 points on the serial sevens from 100 and 1 point on the 3 stage command. However, his ADL was normal. He had no neurologic deficits at motor, sensory, coordination and gait tests. After 20 days from administering ALC with a dose of 1,500 mg per day for improving cognitive decline, he

also suffered from vivid dreams at every night. He had 2 or 3 separate dreams that were graphic and vivid. The contents of his dream were standing surrounded colorful wall. And sometimes, his dream included familiar games called 'go-stop' with his friend. His dreams were too vivid to distress at night. In addition, his mornings were not fine and did not feel refreshed because of the dreams. His sleep was also restored after ceasing the ALC treatment.

DISCUSSION

The rapid eye movement (REM) sleep is distinct behavioral status, characterized by an activated cortical and hippocampal electroencephalogram and concurrent muscle atonia. Commonly, REM sleep is called as a dreaming sleep⁵. Sublaterodorsal (SLD) nucleus which was located just ventral to caudal laterodorsal tegmental nucleus in the brainstem has been suggested as a "REM-on" cell based on several animal studies⁶. The glutamate released from SLD nucleus is critical for regulating REM sleep phenomena⁶.

Under the mechanism of ALC, the high level of serum

carnitine is able to induce the glutamate releasing in SLD⁷⁾. As a result, it is able to enhance "REM-on" cell. Accenting projections of REM-on glutamate neurons might regulate the cortical features of REM sleep. We assumed that the vivid dream in our patients was a final consequence of these responses at high level of serum carnitine.

Dysfunction of fatty acid β -oxidation by abnormal low carnitine levels has been suggested in narcolepsy patient⁶⁾. The deficiency of carnitine causes the fatty acid oxidation disturbances under fasting when fatty acids need to become a major energy source⁷⁾. The orexin neuronal activity, which is an important role in the maintenance of wakefulness, is able to proportionally reduce with the level of serum carnitine⁷⁾. Moreover, prolonged reduced orexin activity resultantly showed fragmentation of sleep and significant decreased amounts of REM sleep.

From all suggestive mechanisms, associated with carnitine metabolism, we suggested that overdose supplementation of carnitine could induce the dysfunction of fatty acid β -oxidation, increasing orexin neuronal activity and glutamate releasing from SLD⁸⁾.

In addition, ageing is able to cause a number of changes in drug absorption, distribution and elimination. Therefore, the pharmacologic effect that is previously mentioned of ALC could be strengthened in elderly⁹⁾. When we prescribe medicines to elderly with any purpose, we should have the pharmacologic changes of elderly in our mind.

However, there are some weak points to suggest vivid dreams after carnitine supplementations in our patients with cognitive declines.

First, we did not evaluate the level of serum carnitine before and after oral administration in each patient. Nevertheless, these two patients revealed suffering from vivid dreams within 2 weeks from carnitine administrations in same, and relieved after ceasing the ALC medications. We suggested that it could be an evidence for carnitine effects for vivid dreams.

Second, we felt the lack of this study for overnight sleep such as polysomnography, which is the best study for sleep quality and structure. However, polysomnography is not able to reveal whether the dream is vivid or not. It is only able to evaluate the amount of REM in proportion to the total sleep time. We thought the report about sleep problems by patients after nights were reliable to evaluate the dream contents.

Third, there were no exact pathomechanism for REM sleep disorder, such as nightmare, REM sleep behavior disorder and sleep related hallucination. The orexin neuronal activity, glutaminergic neuron in SLD have been just suggested a major neurotransmitters in REM sleep. In addition to these classical neurotransmitters, there are more considerable neurotransmitters and neuromodulators to influence the sleep regulation, including REM sleep.

In summary, oral ALC administration might present as vivid dream problems. This possibility should be considered during the management with oral carnitine, and should be checked for any possible sleep problems, including dream enhancing sleep disorders in patients treated with carnitine.

REFERENCES

1. Malaguarnera M. Carnitine derivatives: clinical usefulness. *Curr Opin Gastroenterol* 2012;28:166-76.
2. Mingorance C, Rodriguez-Rodriguez R, Justo ML, Alvarez de Sotomayor M, Herrera MD. Critical update for the clinical use of L-carnitine analogs in cardiometabolic disorders. *Vasc Health Risk Manag* 2011;7:169-76.
3. Rai G, Wright G, Scott L, Beston B, Rest J, Exton-Smith AN. Double-blind, placebo controlled study of acetyl-L-carnitine in patients with Alzheimer's dementia. *Curr Med Res Opin* 1990;11:638-47.
4. Malaguarnera M, Gargante MP, Cristaldi E, Colonna V, Messano M, Koverech A, et al. Acetyl L-carnitine (ALC) treatment in elderly patients with fatigue. *Arch Gerontol Geriatr* 2008;46:181-90.
5. Krenzer M, Anadet C, Vetrivelan R, Wang N, Vong L, Lowell BB, et al. Brainstem and spinal cord circuitry regulating REM sleep and muscle atonia. *PLoS One* 2011;6:e24998.
6. Tanaka M, Nakamura F, Mizokawa S, Matsumura A, Matsumura K, Watanabe Y. Role of acetyl-L-carnitine in the brain: revealed by Bioradiography. *Biochem Biophys Res Commun* 2003;306:1064-9.
7. Yoshida G, Li MX, Horiuchi M, Nakagawa S, Sakata M, Kuchiiwa S, et al. Fasting-induced reduction in locomotor activity and reduced response of orexin neurons in carnitine-deficient mice. *Neurosci Res* 2006;55:78-86.
8. Miyagawa T, Miyadera H, Tanaka S, Kawashima M, Shimada M, Honda Y, et al. Abnormally low serum acylcarnitine levels in narcolepsy patients. *Sleep* 2011;34:349-53, 353A.
9. Cho KH. Adverse drug reaction in the aged. *J Korean Geriatr Soc* 1998;2:8-11.